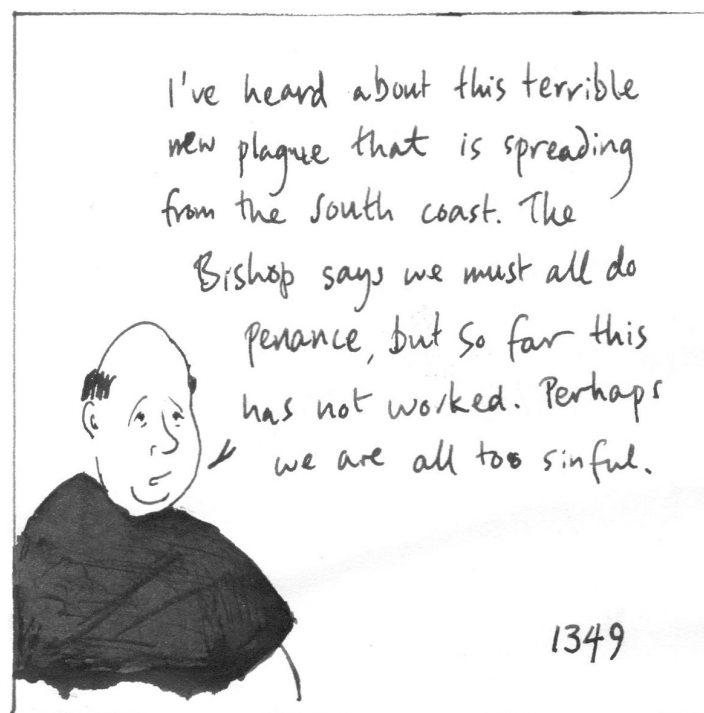


Actual Priory skeleton with healed fracture





The canons of Merton Priory were fairly healthy. Skeletons show some tooth decay and some well-healed fractures. One skeleton had bone cancer. 4 had syphilis! Lots had diffuse idiopathic skeletal hyperostosis (DISH) - an arthritic condition probably caused by eating too much meat!



Merton Priory managed to avoid being hit by the Black Death in 1348-9, but in later outbreaks in the 1360s, it killed two of Merton's priors, and probably other Priory inhabitants. Plague hit again 8 times before Merton Priory was dissolved in 1537.